

OSTEOPATHIES IN THE POPULATION OF OLD IASI CITY (ROMANIA): THE NECROPOLIS OF THE “BANU” CHURCH, 16TH-19TH CENTURIES

Vasilica-Monica GROZA¹, Angela SIMALCSIK¹, Luminița BEJENARU^{1,2} and Robert-Daniel SIMALCSIK¹

¹Romanian Academy – Iași Branch, Department of Anthropological Research, Str. Th. Codrescu, no. 2, Iași, Romania, antropologie.iasi@yahoo.com, moni_ian@yahoo.com

²“Alexandru Ioan Cuza” University, Faculty of Biology, Bd. Carol I, 20A, Iași, 700505, Romania

Abstract. This study describes the incidence and the analysis of a series of osteopathies observed in the skeletal series found in the necropolis of the ancient “Banu” Church of Iași City (Romania). According to the authors of the excavations, the necropolis was used between the first half of the 16th century and the beginning of the 19th century. The osteological material consisting of 67 skeletons (children, teenagers, adults, mature and senile) derives from both individual tombs and reinterment tombs. The distribution by gender and by age categories indicates a higher male mortality rate as opposed to females, resulting in a higher masculinity index. Most deaths were recorded in the *maturus* category (59.70%), followed by *infans* I and II (26.15%), *senilis* (5.97%), *juvenis* (4.48%) and *adultus* (2.99%). The incidence of pathologies, anomalies and non-metric features was estimated both separately by gender and for the entire osteological sample. In the cranial segment (for the entire osteological series), wormian bones and metopic suture have equal incidence – 2.98%, followed by porotic hyperostosis, cribra orbitalia, and premature synostosis of the sagittal suture (with equal incidence – 1.49%). In the post-cranial segment, extra facets of the tibia recorded 8.98%, followed by osteoarthritis (7.46%) and supratrochlear foramen of the humerus (5.97%). Lower incidences were recorded for spina bifida occulta and spondylolysis (2.98% each).

Keywords: Iași City, 16th-19th centuries, necropolis, skeletal series, osteopathies

Rezumat. Osteopatiile la populația vechiului oraș Iași (România): necropola Bisericii „Banu”, secolele XVI-XIX. Lucrarea prezintă incidența și studiul unor osteopatii semnalate la seria osteologică deshumată din necropola situată în incinta Bisericii „Banu” din orașul Iași (România). Conform autorilor săpăturii arheologice, limitele de folosire în timp a necropolei se situează între prima jumătate a secolului al XVI-lea și începutul secolului al XIX-lea. Materialul osteologic reprezentat prin 67 de schelete (copii, adolescenți, adulți, maturi și senili) provine atât din morminte individuale cât și din morminte cu reînchumări. În urma repartizării pe sexe și pe categorii de vârstă s-a constatat o pondere mai mare a bărbaților comparativ cu femeile, ceea ce indică un indice de masculinitate mai crescut. Semnalăm o predominanță a deceselor în intervalul *maturus* (59,70%), urmate de categoriile *infans* I și II (26,15%), *senilis* (5,97%), *juvenis* (4,48%) și *adultus* (2,99%). Prezența patologiilor, anomaliilor și a caracterelor non-metriche a fost calculată atât separat pe sexe, cât și pentru întregul eșantion osteologic. La nivelul segmentului cranian (pentru întreaga serie scheletică), oasele wormiene și sutura metopică prezintă procente egale – 2,98% urmate de hiperostoza porotică, cribra orbitalia și sinostozarea prematură a suturii sagitale (cu procente egale – 1,49%). În segmentul postcranian, fațetele suplimentare pe articulația tibio-talară înregistrează un procent de 8,98%, urmate de osteoartrită (7,46%) și foramenul humeral supratrochlear (5,97%). Frecvențe reduse au înregistrat spina bifida occulta și spondiloliza (procente egale – 2,98%).

Cuvinte cheie: orașul Iași, secolele XVI-XIX, necropolă, serie de schelete, osteopatii

Introduction

It is a well known fact that bone diseases (the incidence and gravity of osteopathies) are used as “markers” for advanced ages, but they can also be associated with hygienico-sanitary conditions (infections), diet, hard labour, carrying burdens, etc.

Paleopathology analyses the origins of diseases, their spreading, dynamics, evolution and progress for long periods of time, as well as the way people adapted to changes in their environment (Gładykowska-Rzeczycka, 2004-2006; Roberts & Manchester, 2005). It is also used to evaluate the ancient populations' biological structure, when historical sources provide very little information (Gładykowska-Rzeczycka, 2004-2006). Pathological aspects are induced by the interaction between genetic and non-genetic factors (the latter deriving from the environment). Bone anomalies are changes in the normal bone structure induced by disruptions of the chemical or metabolic functions under the influence of exogenous, genetic or teratogenic factors (Gregg & Gregg, 1987). Bone anomalies can appear before or after birth and they range from less serious forms to major and sometimes lethal anomalies (Barnes, 1994; Masnicová & Beňuš, 2003). Most frequently encountered in the human skeleton are bone fusion, ossification and underdevelopment anomalies and agenesis, all of these identified in numerous prehistoric and historic osteological series around the world (Zimmerman & Kelley, 1982).

Non-metric features (also called epigenetic, discontinuous morphological or discrete traits) are forms of variations observed in the bone structure. Non-metric features are hereditary to a certain extent and for that matter they can be used in research concerning ancestral connections; however their genetic foundation is unclear (Carson, 2006).

Archaeological research conducted on the premises of the current "Banu" Church of Iași City within an edifice rehabilitation project brought to light a piece of the old church necropolis. The necropolis was discovered and excavated in 2011 by Mrs. Stela Cheptea, PhD and C.S. I archaeologist, and her collaborators at the Centre for European History and Civilization within the Iași Branch of the Romanian Academy.

The old church was dated from 1705 (Bogdan, 1997-2004), and it was known at the time under the name of "The Falling Asleep of the Virgin Mary" Church. In his monograph on the city of Iași, N.A. Bogdan (1997-2004) mentions that during the 1650 Kazakh invasion, the wooden church was burnt down and a new majestic Baroque edifice made of stone was built in its stead in 1800 – the current "Banu" Church. According to the data provided by the authors of the excavations, the necropolis was used between the first half of the 16th century and the beginning of the 19th century.

This study intends to analyze the incidence and characteristics of specific pathologies, anomalies and non-metric features observed in the osteological series exhumed from the necropolis located on the premises of the "Banu" Church of Iași.

Material and Methods

The osteological material consisting of 67 skeletons (children, teenagers, adults, mature and senile) comes from both numbered tombs (individual for the most part – skeletons noted with "M"), but mostly from reinterment tombs (skeletons noted with "R"). In the total of 67 skeletons, there were 18 children, three teenagers, two adults, 40 mature and only four senile people. In most cases, the precarious state of preservation, as well as the skeleton deterioration during excavations, impeded us to abide strictly by the analysis stages. The bone fragments were subjected to a thorough morphoscopic analysis, which determined each skeleton's age and gender, anomalies, pathologies and the epigenetic features of the cranial and post-cranial bones. In order to determine the gender, we considered a set of features, using all the bone pieces which provided us with metric and morphological data. Thus, we analyzed the shape of the pelvis, the opening of the greater

sciatic foramen, the sacral curvature, the robustness of the long bones, the development of the joints and muscle insertions, the development of the cranial relief, the forehead's shape and degree of inclination, the mandible robustness, the shape and type of the mandibular mentonian region and the teeth shape and size.

So as to establish the age at death, we used all the criteria recommended by classical methodology. For the subjects under 20, we examined: the primary teeth eruption, the permanent teeth eruption, the dental buds stages of development, the long bones epiphyses fusion with the respective dyaphyses and the fusion of the epiphyseal discs with the vertebrae. For the subjects under 20 (*infans I*, *infans II* and *juvenis*), the age at death was established according to the methodology suggested by Maresch (1955, 1970), Moorrees *et al.*, (1963), Trotter & Peterson (1969), Fazekas & Kosa (1978), Ubelaker (1979), Jeanty (1983) and Schaefer *et al.*, (2009).

For the subjects past 20, the features we used to determine the age at death were: changes in the symphyseal surface and the sacropelvic surface of ilium, changes in the spongy tissue found in the epiphyses of the humerus and femur, certain skeletal involution phenomena and the existence of pathological processes that can be associated with aging, cranial suture obliteration and masticatory surface abrasion. The gender and age at death for the subjects past 20 (*adultus*, *maturus* și *senilis*) was determined using the methods, criteria and techniques recommended by Ferembach *et al.*, (1979), Ubelaker (1979), Brothwell (1981), Buikstra & Ubelaker (1994), Bruzek (2002), Walrath *et al.*, (2004) and Schmitt (2005).

Pathologies, anomalies, and cranial and post-cranial non-metric features were subjected to a thorough analysis. In order to identify them, we used the methods, criteria and techniques recommended by Mays (1998), Waldron (2009), Ortner (2003), Aufderheide & Rodriguez-Martin (1998) and Barnes (1994).

Results and Discussion

In the total of 67 skeletons subjected to the study, we identified 21 subadults (*infans I*, *infans II* and *juvenis*) and 46 subjects past the age of 20 (*adultus*, *maturus* and *senilis*). Subadult mortality rate, including the subjects between 0 and 20 years, has significant values (17.19% for *infans I*, 8.96% for *infans II* and 4.48% for *juvenis*), which means that more than one third of the population (31.35%) didn't reach adulthood. In the interval 20-x years, the highest number of deaths was recorded in the *maturus* category (59.70-32.84% for men and 26.87% for women), whereas in the *adultus* and *senilis* categories, the mortality rate is considerably lower (*adultus*: 2.99% for men; *senilis*: 5.97-4.48% for men and 1.49% for women).

The analysis of mortality by gender revealed a higher male mortality rate (29 men as opposed to 20 women, with a masculinity index of 1.45). This disparity was observed in all the age groups (juvenile, adult, mature and senile).

The incidence of osteopathies in the osteological series discovered on the premises of the “Banu” Church of Iași (16th-19th centuries) is presented in Table 1. Values were calculated both for the two genders (29 men and 20 women) and for the entire lot (67 subjects). Due to the precarious preservation of the subadults and the fact that certain osteopathies become obvious later in life, we only identified a child supratrochlear foramen of the humerus.

In the *cranial segment* (for the entire osteological series), we identified wormian bones and metopic suture (with equal incidence – 2.98%), followed by porotic hyperostosis, cribra orbitalia and premature sagittal suture closure (also with equal incidence – 1.49%) (Table 1).

Porotic hyperostosis, also known as exocranial porosity or external cribra cranii, appears due to abnormal increase in the bone tissue on the exocranium. The presence of porotic hyperostosis can allude to various diseases, such as: infantile scurvy, rickets, iron deficiency anemia, osteitis, osteomyelitis, periostitis, inflammatory processes of the cranial bones and skull or post-mortem osseous changes (Ortner, 2003; Walker *et al.*, 2009). Porotic hyperostosis is one of the most frequently studied indicators of the subjects (skeletons) state of health, also providing valuable information about the environmental conditions during growth and development (Vercellotti *et al.*, 2009).

In the skeletal series discovered on the premises of the “Banu” Church of Iași, porotic hyperostosis was identified in a single skull (1.49% of the total population), which belonged to a female aged circa 30-35 years (Fig. 1).

Table 1. Incidence of pathologies, anomalies and non-metric bone features in the skeletal serie exhumed from the necropolis of the “Banu” Church of Iași (16th-19th centuries).

Pathologies/anomalies/ non-metric features		Men (14-x years)		Women (14-x years)		Children (0-14 years)		Total	
		N	(%)	N	(%)	N	(%)	N	(%)
Cranial segment	porotic hyperostosis*	-	-	1/20	5	-	-	1/67	1.49
	cribra orbitalia*	1/29	3.44	-	-	-	-	1/67	1.49
	premature sagittal suture closure**	1/29	3.44	-	-	-	-	1/67	1.49
	metopic suture***	1/29	3.44	1/20	5	-	-	2/67	2.98
	wormian bones***	2/29	6.89	-	-	-	-	2/67	2.98
Post-cranial segment	osteoarthritis (Schmorl’s nodules, osteophytes, bone erosion)*	5/29	17.24	-	-	-	-	5/67	7.46
	spina bifida occulta**	2/29	6.89	-	-	-	-	2/67	2.98
	vertebral spondylolysis**	1/29	3.44	-	-	-	-	1/67	2.98
	supratrochlear foramen of humerus***	2/29	6.89	1/20	5	1/18	5.55	4/67	5.97
	extra facets on tibiotalar joint***	5/29	17.24	1/20	5	-	-	6/67	8.98

* Pathologies; ** anomalies; *** non-metric features.

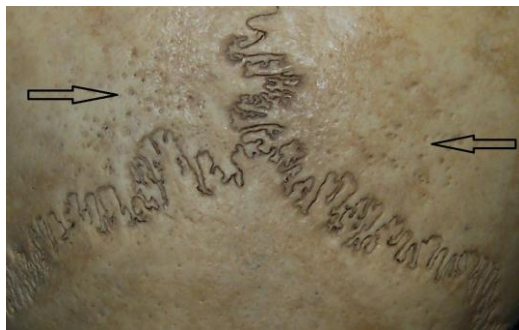


Figure 1. Porotic hyperostosis in parietal bones (R12, ♀, 30-35 years).

Another pathology we identified in the cranial segment is *cribra orbitalia* (*exocranial orbital porosity*) which appears as a point-like corrosion of the external compact layer of the orbital roof and the thickening of the spongy bone layer (Kozak & Krenz-Niebal, 2002). The presence of this porosity alludes to an iron deficiency in the organism, due to insufficient dietary intake of iron or an environment laden with pathogenic agents (Stuart-Macadam, 1992). In the case in which there is no additional proof to support this deficiency (such as a histological survey), experts recommend caution when establishing a final diagnosis of iron deficiency anemia. Thus, in the absence of exact diagnosis methods, other than simple morphoscopic examination, *cribra orbitalia* is a non-specific indicator of diseases (Aufderheide & Rodriguez-Martin, 1998; Wapler *et al.*, 2004).

In some cases, we encountered both *cribra orbitalia* and porotic hyperostosis in the same subject, which is a solid argument supporting the theory that the two affections are consequences of the same systemic problem. *Cribra orbitalia* is more frequently encountered than porotic hyperostosis. If *cribra orbitalia* represented an earlier and less serious expression of the pathological process which also determines porotic hyperostosis, it could explain the much higher incidence of this pathology (Walker *et al.*, 2009).

In the present study, *cribra orbitalia* was identified in a single subject (1.49% of the total population) – a teenager aged 16-18 (Fig. 2).

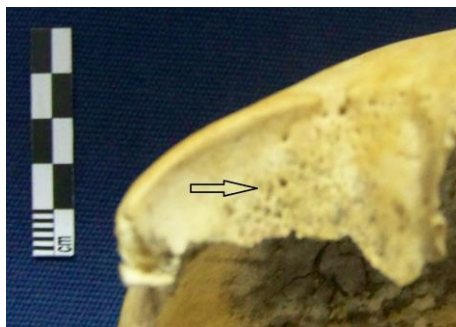

Figure 2. *Cribra orbitalia* in the right orbit (M 37-A, ♂, 16-18 years).

Premature fusion of the cranial sutures (agenesis). Craniosynostosis appears between the ages of 30 and 40 years on the internal surface and 10 years later on the external surface. The fusion normally begins in the bregma point and then expands successively to the sagittal, coronal and lambdoid suture. Thus, craniosynostosis (premature fusion of the cranial sutures) can be considered a normal process which appears at an abnormally early age. Craniosynostosis or suture agenesis can appear as an isolated case or as part of polytropic syndromes (Aufderheide & Rodriguez-Martin, 1998). The connection between cranial malformations and craniosynostoses was suspected from the beginning of the 19th century and throughout the next decades and it became obvious that some of these craniosynostoses were associated with other congenital anomalies (David *et al.*, 1982).

In the total population we analyzed, premature fusion of the sagittal suture was identified in a single case (1.49%), in a male aged 18-20 years (Fig. 3).

Metopic suture is located between the frontal bones, from the anterior point of the anterior fontanelle to the glabella. The fusion of the metopic suture begins from the glabella, advances progressively to the upper area and ends at the anterior fontanelle

(Weinzweig *et al.*, 2003). Metopic suture normally closes between the first and the second year of life and is usually completely fused by the age of three, but it can sometimes remain open until the age of seven. Also, in some cases metopic suture remains open throughout life and it can be identified even in elders (Ide *et al.*, 2003; Nakatani *et al.*, 1998).

In the studied osteological series, metopic suture was identified in two subjects (2.98% of the total population), specifically a male aged 40-45 years (Fig. 4) and a mature female (50-55 years) (Fig. 5).




Figure 3. Skull, vertical norm, premature fusion of the sagittal suture (R 5, ♂, 18-20 years).

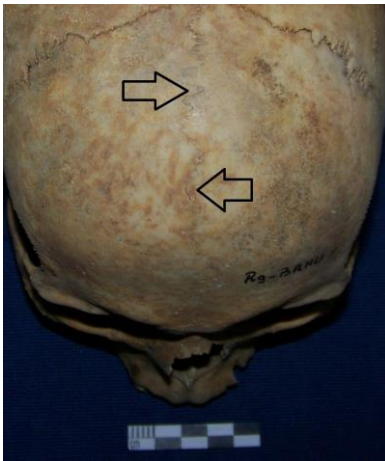


Figure 4. Frontal bone, metopic suture (R 9, ♂, 40-45 years).




Figure 5. Frontal bone (incomplete), metopic suture (R 17, ♀, 50-55 years).

Wormian bones, also called *intersutural bones* or *Inca bones*, are small bones that appear within cranial sutures. Their number and shape can vary from one person to another. They are present in the frontal and occipital bones and in some cases they lead to erroneous diagnoses of the cranial fractures (Nayak, 2008). Wormian bones can be a common occurrence and they seem to be genetically conditioned in some populations (Kaplan *et al.*, 1991). Although the mechanisms responsible for the appearance of wormian bones are unknown, some studies indicated that their presence can be useful in identifying anomalies of the skull and central nervous system (Pryles & Khan, 1979; Das *et al.*, 2005).

In the total number of subjects we analyzed, wormian bones (within the lambdoid suture) were identified in two males (2.98% of the population) aged between 35 and 50 years (Figs 6; 7).



Figure 6. Two wormian bones within the lambdoid suture (one bone 23.5 mm long and 12.5 mm wide) (R 8, ♂, 35-40 years).

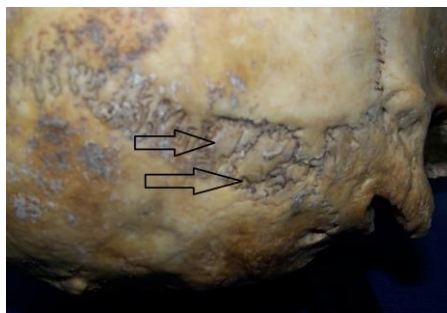


Figure 7. Two wormian bones within the lambdoid suture (M 29, ♂, 50 years).

In the *post-cranial segment* (for the entire osteological series), the highest incidence was recorded by extra facets on the tibiotalar joint (8.98%), osteoarthritis (7.46%) and supratrochlear foramen of the humerus (5.97%). Spina bifida occulta and spondylolysis had lower incidences (2.98% each) (Table 1). An important observation is that the female gender appears less pathologically conditioned in comparison with the male gender, regardless of the skeletal segment (cranial or post-cranial). This claim has some reservations due to the smaller number of female subjects (the studied series consists of 67 subjects and the sex ratio is 29/20).

Osteoarthritis is a degenerative joint disease caused by cartilage loss in a joint. This leads to lesions due to direct contact between the bones and in the attempt to repair the lesion, the joint's bone reacts by producing another bone (Aufderheide & Rodriguez-Martin, 1998).

Osteoarthritis generally affects the hip, hand, knee, lumbar and neck joints. We noticed that after the age of 50, women are much more frequently affected by osteoarthritis in comparison with men (Lawrence *et al.*, 2008). The cause determining osteoarthritis is yet unknown, however there are certain factors which amplify the risk of developing this disease, such as: heredity, overweight, joint lesions, repeated overstrain in certain joints, lack of physical activity, nervous lesions and aging. The study of a genealogical database concerning the population of Iceland revealed that hand osteoarthritis and hip osteoarthritis

are strongly influenced by genetic inheritance, spreading over several generations (Jónsson *et al.*, 2003).

In the analyzed skeletal series, osteoarthritis was identified in five male subjects (aged 40-65 years) (7.46% of the total population), being mainly represented by osteophytes (Figs 8; 9), Schmorl's nodules (Fig. 10) and bone porosity (corrosion) (Figs. 11; 12).



Figure 8. Dorsal vertebrae, marginal osteophytes (M 11, ♂, 45-50 years).

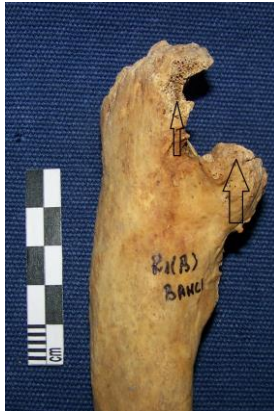

Figure 9. Left cubitus, osteophytes in the superior epiphysis (R 1(B), ♂, 40-45 years).

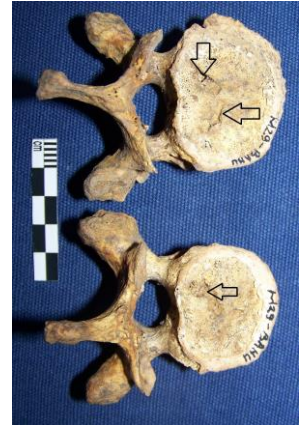

Figure 10. Dorsal vertebrae, Schmorl's nodules (M 29, ♂, 50 years).

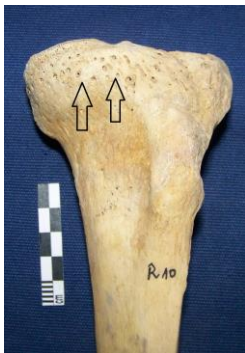

Figure 11. Left tibia, bone porosity (corrosion) (R 10, ♂, 55-60 years).

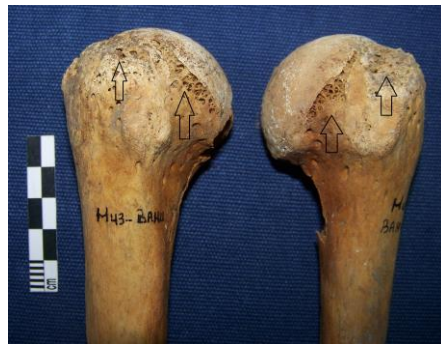

Figure 12. Humeri, porosity (corrosion) in the shoulder joint area (M 43, ♂, 60-65 years).

Spina bifida occulta (occult spinal dysraphism)

Spina bifida (spinal dysraphism, spinal defect, neural tube defect, open spine) includes all forms of congenital spine abnormalities resulting in a faulty neural arch which allows the meninx or neural elements to herniate (Dawson, 2006). Spina bifida has multifactor origins, including a genetic predisposition and environmental factors; nevertheless, the exact cause remains unknown (Windham & Bjerkedal, 1982). In the past decade, scientists noticed that folic acid, zinc and selenium deficiencies in the maternal metabolism can lead to neural tube defects in the embryo. The three nutritional substances

are necessary for the genetic control of cell growth during morphogenesis (Barnes, 1994). Consequently, maternal diet, exposure to teratogenic factors and genetic predisposition acting together can lead to spinal dysraphism.

Occult spinal dysraphism can be located on any spinal segment, starting at the atlas and ending at the sacrum; however, it is most frequently encountered in the lumbosacral region (L5-S1), recording incidences up to 25% (Barnes, 1994). Epidemiologic studies have revealed a wide variation in the prevalence of spina bifida based on ethnicity, race, geography and temporal trends (Josan *et al.*, 2008). Paleoanthropological research concerning spina bifida was centered on the sacrum bone. Sacral spina bifida occulta was frequently identified and reported by paleopathologists as a congenital anomaly (Kumar & Shane Tubbs, 2011).

Sacral spina bifida occulta (sacral occult spinal dysraphism) was recorded in two male subjects (2.98% of the total population) aged between 18-55 years, in the segments S4-S5 and S3-S5, respectively (Figs 13; 14).

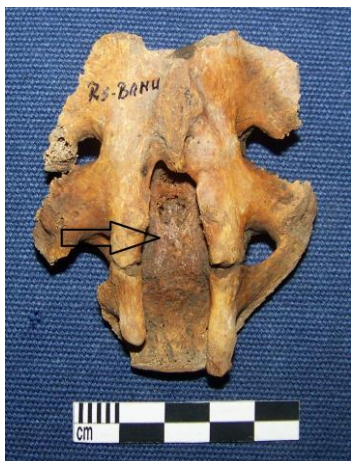

Figure 13. Sacrum, sacral spina bifida occulta (segment S4-S5) (R 5, ♂, 18-20 years).

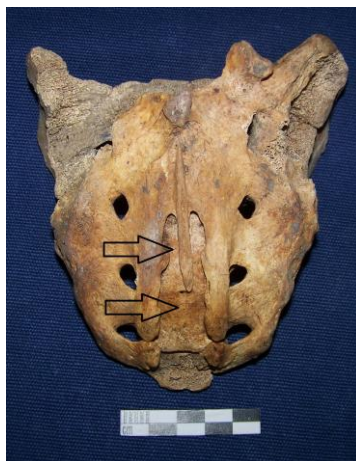

Figure 14. Sacrum, spina bifida occulta (segment S3-S5) (M 45, ♂, 50-55 years).

Vertebral spondylolysis

Spondylolysis can be described as an ossification failure in the pars interarticularis area of the vertebra, leading to its separation in two parts: a ventral part consisting of the vertebral body and a dorsal part represented by the spinous process and the inferior articular process (Aufderheide & Rodriguez-Martin, 1998). L3-L5 lumbar vertebrae, respectively the first sacral vertebra (S1) are the most frequently affected. Bilateral spondylolysis is most frequently encountered in males (Barnes, 1994).

In the studied series, lumbar spondylolysis in the L4 vertebra was identified in a single case (2.98% of the total population), specifically a male aged 45-50 years (Fig. 15).

Supratrochlear foramen of the humerus is considered by some authors an atavism (Mahajan, 2011), whereas others (Singhal & Rao, 2007) see it as a result of bone atrophy after ossification, induced by the mechanical pressure of the olecranon process over the supratrochlear area of the humerus, resulting in the atrophy of the olecranon process.

In the studied series, supratrochlear foramen of the humerus (olecranian

perforation) was identified in four subjects (5.97% of the total population), specifically two men (aged 18-40 years) (Figs 16; 17), a woman (aged around 60) (Fig. 18) and a child (13-14 years) (Fig. 19).

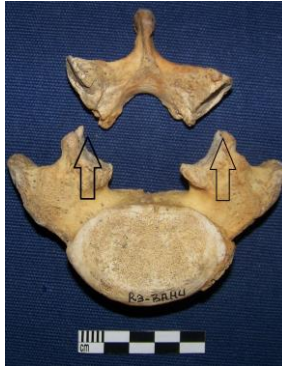

Figure 15. Lumbar vertebra (L4), bilateral spondylolysis (R 3, ♂, 45-50 years).

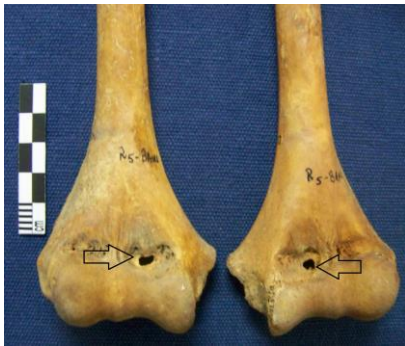

Figure 16. Humeri, supratrochlear foramen (R 5, ♂, 18-20 years).

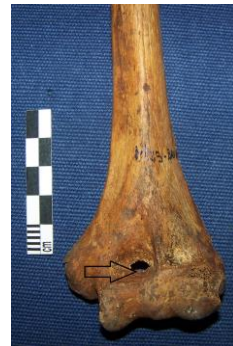

Figure 17. Left humerus, supratrochlear foramen (M 23, ♂, 35-40 years).



Figure 18. Left humerus, supratrochlear foramen (M 33, ♀, 60 years).

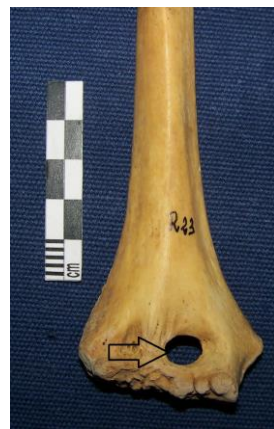

Figure 19. Right humerus, supratrochlear foramen (R23, 13-14 years).

Extra facets on the tibiotalar joint are caused, according to some authors (Tulsi & Prasada Rao, 1968) by mechanical stress (the habit of squatting), whereas others (Satinoff, 1972) see it as a post-cranial epigenetic trait. The study of heredity revealed that the squatting facet can be seen on the tibia and the talus during the fetal period and during childhood. With age, if squatting is no longer part of the daily routine, the associated facet disappears. Consequently, the main reason which determines the appearance of this facet is represented by the frequent squatting movements (Baykara *et al.*, 2010).

Extra facets on the inferior tibial epiphyses were identified in five men aged 35-60 years (Figs. 20-24) and a woman aged 55-60 years (8.98% of the total population) (Fig. 25).

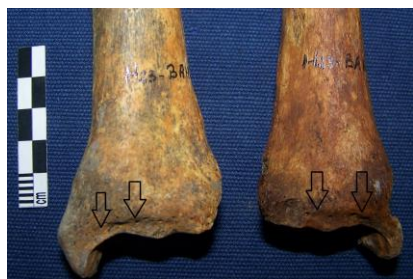

Figure 20. Tibiae, extra facets on the joint (M 23, ♂, 35-40 years).



Figure 21. Right tibia, extra facet on the joint (M 39, ♂, 40 years).

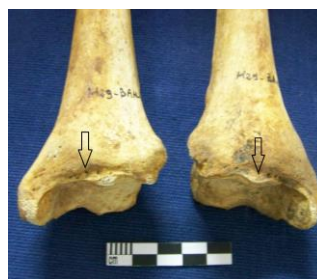

Figure 22. Tibiae, extra facets on the joint (M 29, ♂, 50 years).



Figure 23. Left tibia, extra facets on the joint (R 16 (A), ♂, 50-55 years).

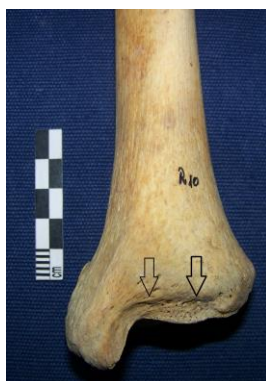

Figure 24. Left tibia, extra facets on the joint (R 10, ♂, 55-60 years).

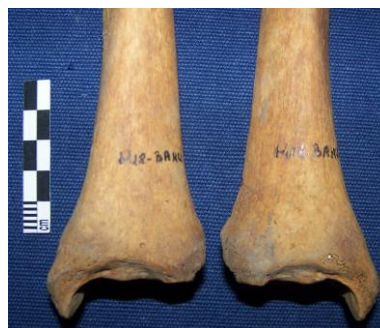

Figure 25. Tibiae, extra facets on the joint (R 10, ♂, 55-60 years).

Conclusions

The osteological material analyzed in this study was exhumed in 2011 under the guidance of the archaeological team from the Centre for European History and Civilization of Iași. Archaeological excavations brought to light 67 human skeletons found in inhumation tombs (individual or reinterments). This skeletal series represents a small segment of the population inhabiting the city of Iași during the 16th-19th centuries.

The distribution by gender of the 67 skeletons revealed a significant child mortality rate (0-14 years: about 27%), a maximum incidence of death in the mature range (30-60 years: about 60%) and a relatively low mortality rate after the age of 60. We observed a higher male mortality rate (43.28% for men as opposed to 29.85% for women).

Paleopathological aspects, linked to the main paleodemographic indicators, can provide valuable information about the environmental and socioeconomic conditions in which this population performed its daily activities.

If we refer to the entire skeletal series, the main indicators of the state of health in the cranial segment are cribra orbitalia and porotic hyperostosis, with equal incidence (1.49%). The presence of these exocranial porosities is frequently used as an instrument to evaluate the state of health and the nutritional status of the past populations; at present, they are also regarded as potential indicators of the environmental conditions. Among the types of anomalies, we identified premature fusion of the cranial sutures (craniosynostosis produced at an abnormally early age), with an incidence of 1.49%. Non-metric (epigenetic) features such as wormian bones and metopic suture identified in the cranial segment (with equal incidence – 2.98%) can be inherited and for that matter they can be used in studies concerning the biological affinity of the human populations from the past.

In the post-cranial segment of the analyzed series, osteoarthritis related affections (Schmorl's nodules, osteophytes, bone corrosion – 7.46%) were identified exclusively in males aged between 40 and 65 years, being mainly located in the spine and the joints of appendicular skeleton. The main factors responsible for this affection are age and genetic predisposition; however certain physical activities also play an important role in the matter.

The presence of non-metric features such as the supratrochlear foramen of the humerus (5.97%) and extra facets on the tibiotalar joint (8.98%), indicates that the subjects practiced intense physical activities which strained their arms (repetitive flexion and extension movements) and that they spent a lot of time in the squatting position or doing many repetitive genuflexions. The only anomalies identified in the post-cranial segment for this population were spina bifida occulta and vertebral spondylolysis, with equal incidence (2.98%).

An important observation is that the male gender appears more pathologically conditioned in comparison with the female gender, regardless of the skeletal segment (cranial or post-cranial).

Acknowledgements

We thank Mrs. Stela Cheptea, PhD (C.S. I archaeologist at the Centre for European History and Civilization, Iasi) for the osteological material made available for the anthropological study.

References

- Aufferheide, A.C., Rodriguez-Martin, C., 1998. *The Cambridge Encyclopedia of Human Paleopathology*. Cambridge University Press.
- Barnes, E., 1994. *Developmental Defects of the Axial Skeleton in Paleopathology*. University of Colorado: Niwot, Colorado.
- Baykara, I., Yılmaz, H., Gültekin, T., Güleç, E., 2010. Squatting Facet: A Case Study Dilkaya and Van-Kalesi Populations in Eastern Turkey. *Collegium Antropologicum*, **34** (4): 1257-1262.
- Bogdan, N.A., 1997-2004. *Oraşul Iaşi – Monografie istorică și socială ilustrată* (ediția a III-a). Editura Tehnopress, Iași, p. 228-229.
- Brothwell, D.R., 1981. *Digging up Bones*. Cornell University Press, London.

- Bruzek, J., 2002. A method for visual determination of sex, using the human hip bone. *American Journal of Physical Anthropology*, **117**: 157-168.
- Buikstra, J.E., Ubelaker, D.H., 1994. *Standards for Data Collection from Human Skeletal Remains*. Arkansas Archaeological Survey Research Series No 44, Fayetteville.
- Carson, E.A., 2006. Maximum – likelihood variance components analysis of heritabilities of cranial nonmetric traits. *Human Biology*, **78** (4): 383-402.
- Das, S., Suri, R., Kapur, V., 2005. Anatomical observations on os inca and associated cranial deformities. *Folia Morphologica*, **64**: 118-121.
- David, J.D., Poswillo, D., Simpson, D., 1982. *The Craniosynostoses. Causes, Natural History and Management*. New York, Heidelberg, Berlin: Springer-Verlag.
- Dawson, F., 2006. Spinal Dysraphism. *Medical Bulletin*, **11** (12): 7-11.
- Fazekas, I.Gy., Kosa, F., 1978. *Forensic Fetal Osteology*. Budapest Akademiai Kiado.
- Ferembach, D., Schwidetzky, I., Stloukal, M., 1979. Recommendations pour determiner l'age et le sexe sur le squelette. *Bulletins et Memoires de la Societe d'Anthropologie de Paris*, **XIII**, 6, 1: 7-45.
- Gładkowska-Rzeczycka, J.J., 2004-2006. Palaeopathology in Poland at the beginning of the 21st century. *Studies in Historical Anthropology*, **4**: 25-48.
- Gregg, J.B., Gregg, P.S., 1987. *Dry Bone. Dakota Territory Reflected*. Sioux Printing.
- Ide, Y., Inukai, Y., Yoshida, S., Sato, I., 2003. The internal structure of bony tissue of a human metopic suture by Soft X-ray. *Okajimas Folia Anatomica Japonica*, **79**: 169-173.
- Jeanty, P., 1983. Fetal limb biometry. *Radiology*, **147**: 601-602.
- Jónsson, H., Manolescu, I., Stefansson, S.E., Ingvarsson, TH., Jonsson, H.H., Manolescu, A., Gulcher, J., Stefansson, K., 2003. The inheritance of hand osteoarthritis in Iceland. *Arthritis Rheumatism*, **48**: 391-395.
- Josan, V., Morokoff, A., Maixner, W.J., 2008. Epidemiology and aetiological factors. In: Memet Ö.M., Cinalli G., Maixner W.J. (coord.): *The Spina Bifida. Management and Outcome*. Springer-Verlag Press, 59-65.
- Kaplan, S.B., Kemp, S.S., Oh, K. S., 1991. Radiography manifestations of congenital anomalies of the skull. *Radiology Clinics of North America*, **29**(2): 195-218.
- Kozak, J., Krenz-Niebała, M., 2002. The occurrence of cribra orbitalia and its association with enamel hypoplasia in a medieval population from Kolobrzeg, Poland. *Variability and Evolution*, **10**: 75-82.
- Kumar, A., Shane Tubbs, R., 2011. Spina bifida: a diagnostic dilemma in paleopathology. *Clinical Anatomy*, **24**: 19-33.
- Lawrence, R.C., Felson, D.T., Helmick, C.G., Arnold, L.M., Choi, H., Deyo, R.A., Gabriel, S., Hirsch, R., Hochberg, M.C., Hunder, G.G., Jordan, J.M., Katz, J.N., Maradit Kremers, H., Wolfe, F., 2008. National Arthritis Data Workgroup. Estimates of the prevalence of arthritis and other rheumatic conditions in the United States. *Part II, Arthritis and Rheumatism*, **58** (1): 26-35.
- Mahajan, A., 2011. Supratrochlear foramen; Study of humerus in North Indians. *Professional Medical Journal*, **18** (1): 128-132.
- Mays, S., 1998. *The archaeology of human bones*. Ed. Routledge.
- Mareš, M.M., 1955. Linear growth of long bones of extremities from infancy through adolescence. *American Journal of Diseases of Children*, **89**: 725-742.
- Mareš, M.M., 1970. Measurements from roentgenograms. In: McCammon, R.W. (ed.): *Human Growth and Development*. Springfield, IL: C.C.Thomas.
- Masnicová, S., Beňuš R., 2003. Developmental Anomalies in Skeletal Remains from the Great Moravia and Middle Ages Cemeteries at Devin (Slovakia). *International Journal of Osteoarchaeology*, **13**: 266-274.
- Moorrees, C.F.A., Fanning, E.A., Hunt, E.E., 1963. Age variation of formation stages for ten permanent teeth. *Journal of Dental Research*, **42**: 1490-1502.
- Nayak, S.B., 2008. Multiple Wormian bones at the lambdoid suture in an Indian skull. *Neuroanatomy*, **7**: 52-53.
- Nakatani, T., Tanaka, S., Mizukami, S., 1998. A metopic suture observed in a 91-year-old Japanese mal. *Kaibogaku Zasshi*, **73**: 265-267.
- Ortner, D.J., 2003. *Identification of Pathological Conditions in Human Skeletal Remains*. Elsevier Academic Press.
- Pryles, C.V., Khan, A.J., 1979. Wormian bones. A marker of CNS abnormality?, *American Journal of Diseases of Children*, **133**: 380-382.
- Roberts C., Manchester, K., 2005. *The Archaeology of Disease*. Third Edition, Sutton Publishing Limited, United Kingdom.
- Satinoff, M.I., 1972. Study of the squatting facets of the talus and tibia in ancient Egyptians. *Journal of Human Evolution*, **1** (2): 209-212.
- Schaefer, M., Black, S., Scheuer, L., 2009. *Juvenile osteology*, Elsevier Academic Press.

- Schmitt, A., 2005. Une nouvelle methode pour estimer l'age au deces des adultes a partir de la surface sacro-pelvienne iliaque. *Bulletine et Memoire de la Societe d'Anthropologie de Paris*, **17**(1-2): 1-13.
- Singhal, S., Rao, V., 2007. Supratrochlear foramen of the humerus. *Anatomical Science International*, **82**: 105-107.
- Stuart-Macadam, P., 1992. Porotic Hyperostosis: A New Perspective. *American Journal of Physical Anthropology*, **87**: 39-47.
- Trotter, M., Peterson, R.R., 1969. Weight of bones during the fetal period. *Growth*, **33**: 167-184.
- Tulsi, R.S., Prasada Rao, P.D., 1968. Ilio-tibial facet of the tibia in the Australian Aborigine. *Archaeology & Physical Anthropology in Oceania*, **3**: 232-235.
- Ubelaker, D.H., 1979. *Human Skeletal Remains: Excavation, Analysis and Interpretation*. Smithsonian Institute Press.
- Vercellotti, G., Caramella, D., Formicola, V., Fornaciari, G., Larsen, C.S., 2009. Porotic Hyperostosis in a Late Upper Palaeolithic Skeleton (Villabruna 1, Italy). *International Journal of Osteoarchaeology*, **20** (3): 358-368.
- Waldron, T., 2009. *Palaeopathology*. Cambridge University Press.
- Walker, P.L., Bathurst, R.R., Richman, R., Gjerdrum, T., Andrushko, V.A., 2009. The Causes of Porotic Hyperostosis and Cribra Orbitalia: A Reappraisal of the Iron-Deficiency-Anemia Hypothesis. *American Journal of Physical Anthropology*, **139**: 109-125.
- Walrath, D.E., Turner, P., Bruzek, J., 2004. Reliability test of the visual assessment of cranial traits for sex determination. *American Journal of Physical Anthropology*, **125**: 132-137.
- Wapler, U., Crubezy, E., Schultz, M., 2004. Is cribra orbitalia synonymous with anemia? Analysis and interpretation of cranial pathology in Sudan. *American Journal of Physical Anthropology*, **123** (4): 333-339.
- Weinzweig, J., Kirschner, R.E., Farley, A., Reiss, P., Hunter, J., Whitaker, L.A., Bartlett, S.P., 2003. Metopic synostosis: Defining the temporal sequence of normal suture fusion and differentiating it from synostosis on the basis of computed tomography images. *Plastic and Reconstructive Surgery*, **112**: 1211-1218.
- Windham, G.C., Bjerkedal, T., 1982. Secular trends of neural tube defects by demographic subgroups in Norway. *NIHP Annals*, **5**: 57-67.
- Zimmerman, M.R., Kelley, M.A., 1982. *Atlas of Human Paleopathology*. F.A. Praeger, New York.